

# RISK ALERT



ISSUE 34 JUL 2014

A Risk Management Newsletter for Hospital Authority Healthcare Professionals

## IN THIS ISSUE

### § Sentinel Events (Q1 2014)

- Retained Consumables and Instruments
- Wrong Side Procedure
- Medication Error
- Maternal Death
- Patient Suicide

### § Serious Untoward Events (Q1 2014)

#### § Local Sharing

- Sharing on Reported Near Miss Case
- Medication Incident Statistics (Jul – Dec 2013)

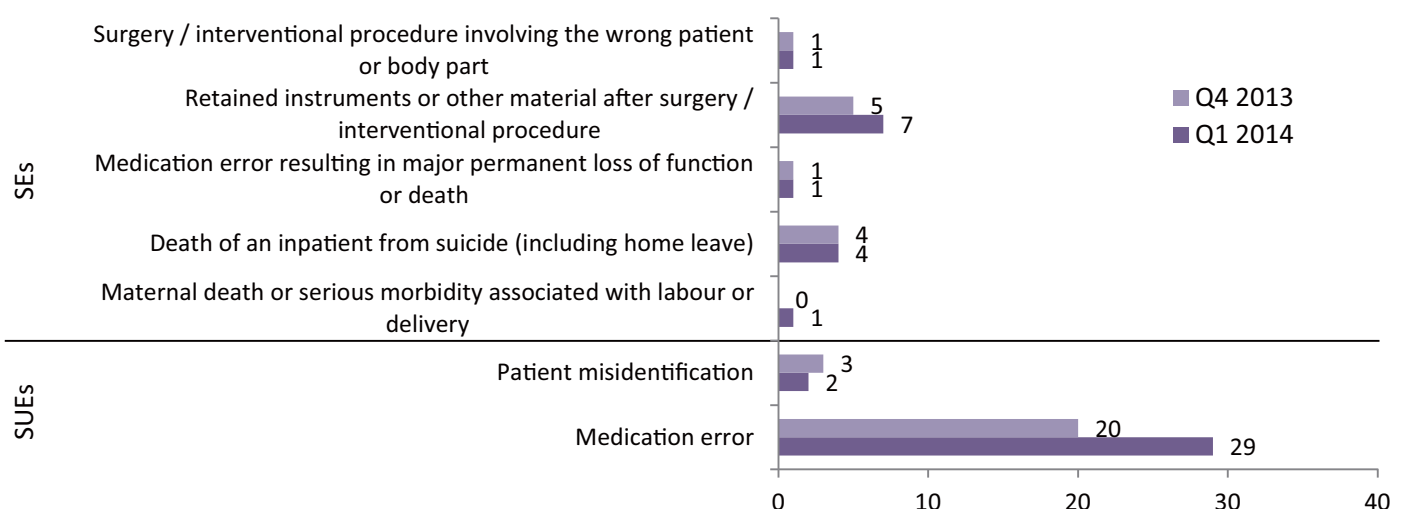
### *Message from Service Director, Quality & Safety Office, Kowloon Central Cluster*

I believe most responsible parents / teachers would like to nurture a positive attitude in their children / students with a view to making their life / world better. While a perfect world does not exist, parents / teachers should inculcate the commendable attitude of striving for perfection or excellence in their children / students. Within the Hospital Authority (HA), there is no doubt that all health carers would like to provide the best possible and safe care to their patients despite all constraints. Yet, to do so would require not only the appropriate attitude and culture to strive for the safest possible practice but also techniques and lessons learnt from previous mishaps.

In every issue of Risk Alert, there are precious lessons with recommended solutions to be learnt. Despite classification of SE / SUE under specific categories, no single incident is identical. Lessons can always be learnt and re-learnt. Although it is unrealistic to aim at zero error in such a big organization as HA with many different individuals working in multidisciplinary or interdisciplinary teams engaged in complex and complicated processes in caring for patients, our desire and effort to lessen risks and harm to our patients should make us different and special. As healthcare professionals, we could adopt pragmatic methods such as automation and strict adherence to protocols and guidelines to ensure safety. However, without the appropriate caring attitude, culture and human touch, we may lose our focus on quality and safety, and mishaps may keep on recurring.

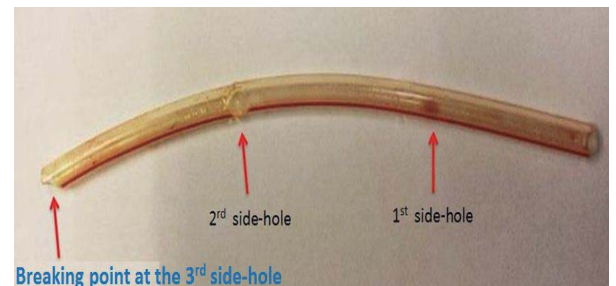
*Dr H F HO, Deputy SD(Q&S), KCC*

## Distribution of Sentinel (SEs) & Serious Untoward Events (SUEs) (Q1 2014)



### 1 Broken silicon wound drain left in abdomen

- A patient had laparoscopic right hemi-colectomy for colon cancer.
- At the end of the operation, the surgeon asked a nurse to cut 3 side holes on a silicon T-tube for use as wound drainage. The silicon tubal drain was subsequently inserted and anchored in position.
- The drain was documented without description of its length or number of side holes on both the operation note and operating theatre nursing record.
- On post-operation day 9, a surgeon requested the nurse to pull out 3 cm of the drain, allowing the site to heal gradually.
- The drain slipped off the next day. Without checking the integrity of the tube or noticing the number of side holes, the nurse discarded the drain upon instruction of a doctor.
- About 3 months later, the patient complained of abdominal pain at out-patient follow up.
- The patient's abdominal X-ray showed a foreign body.
- The remaining 12 cm drain with 2 side holes was then removed surgically. It was found that the drain was broken at the third side hole.
- The patient recovered well.



#### Key Contributing Factors:

1. No standard practice on documentation of the number of side holes created on the wound drain.
2. No standard practice on examination and documentation of the integrity of the removed drain.

#### Recommendations:

1. Enhance documentation of the length of wound drain and number of created side holes in both the operation record and nursing record.
2. Enhance the checking and documentation of the integrity of the slipped-off or removed drain.
3. Encourage the use of appropriate commercial surgical wound drain with holes and markings.

### 2 Broken drill bit in hip replacement wound


- A patient had total hip replacement performed for osteoarthritis.
- The operation was uneventful. "TIME-OUT" was performed as usual.
- Routine check on surgical instrument after disinfection revealed a broken drill bit with a loss of 1cm tip.
- Informed of the finding, the surgeon requested an X-ray examination which showed a shadow.
- The broken drill bit was removed from the patient's lesser trochanter.

#### Key Contributing Factors:

1. Lack of a system to detect fatigue instrument.
2. Failure to detect the missing part of drill bit after use.
3. Problem of metal fatigue and reuse of instrument.

#### Recommendations:

1. Develop a tracking system for detection and replacement of fatigue instruments.
2. Redesign the instrument checking process to ensure timely integrity check.



## 3

## Broken Malecot (PCN) catheter tip in kidney

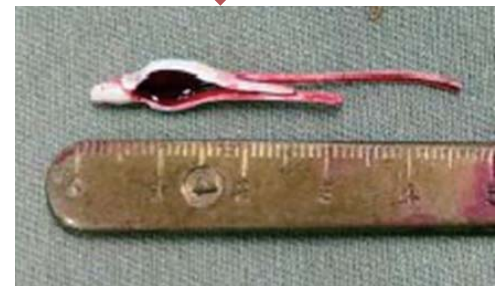- A patient underwent right percutaneous nephrolithotomy (PCNL) for renal stone under local anaesthesia.
- The procedure was abandoned because of the patient's severe pain and hypotension.
- A Malecot catheter was inserted for temporary drainage.
- The patient underwent the second right PCNL under general anaesthesia. The surgeon performed an antegrade pyelogram through the Malecot drain and blockage was noted.
- After removing most of the renal stones by retrograde intrarenal surgery (RIRS), the surgeon decided to remove the right Malecot catheter.
- The removal was met with resistance. The surgeon examined the removed catheter before discarding it but did not notice any irregularity.
- Post-operative X-ray showed a retained Malecot catheter tip.
- The 4.5 cm broken catheter tip was removed surgically.

### Key Contributing Factors:

1. Failure to check integrity of the Malecot catheter immediately after removal.
2. Lack of conscientious team work and effort.
3. Misplacement of Malecot catheter at drainage site during initial PCNL.

### Recommendations:

1. Strengthen the checking and documentation procedure for removed or used surgical material.
2. Reinforce the "speak-up" and "always-kept-informed" culture in the operating theatre.



Broken tip of Malecot catheter

## 4

## A spiral tip of fetal scalp electrode left on an infant's scalp

- For intrapartum fetal monitoring, a fetal scalp electrode was attached directly to the fetus's scalp by an obstetrician.
- The baby was delivered uneventfully and the fetal scalp electrode was removed by a midwife.
- The next day, the baby developed jaundice and was transferred to the neonatal unit for treatment. The baby was discharged home 5 days later.
- About 1 month later, the parents brought the baby to A&E for scalp swelling.
- Skull X-ray revealed a metallic coil in the scalp.
- A 0.5 cm diameter spiral electrode tip was removed eventually.

### Key Contributing Factors:

1. Failure to check completeness of the scalp electrode immediately after removal.
2. Lack of awareness to consider fetal scalp electrode as a countable surgical item in the delivery suite.

### Recommendations:

1. Include the scalp electrode as a countable surgical item and follow the standard checking process for critical items.
2. Establish a good communication system on checking of critical surgical item.



Broken tip of fetal scalp electrode

### 5 Retained PICC internal stiffener stylet

- A patient was managed in an orthopaedic ward for left groin abscess, bilateral ischial decubitus ulcers and infective spondylitis with psoas abscesses.
- The vascular surgical team was consulted for insertion of a Peripherally Inserted Central Catheter (PICC) for a course of intravenous antibiotic over a prolonged duration.
- An unfamiliar brand of PICC was provided to the surgeon performing the procedure.
- The vascular surgical team suspected PICC migration on reviewing a contrast CT scan examination film of the spine which was taken after the procedure to rule out related sepsis.
- The catheter was then removed. It was subsequently confirmed to be the retained PICC internal stiffener stylet which should have been removed at the time of insertion.
- The patient was managed accordingly and discharged home eventually.

#### Key Contributing Factor:

The clinical team was unfamiliar with the device which was used infrequently.

#### Recommendations:

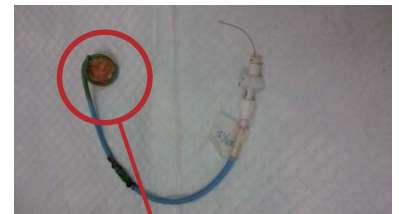
1. Deploy a designated team to perform PICC procedure using new or complex device.
2. Provide orientation and information to staff prior to using a new product.
3. Avoid the use of different brands of product for the PICC procedure.



Internal stiffener stylet

### 6 Retained gauze in complicated abdominal wound

- A patient with long history of Crohn's Disease had numerous hospitalizations.
- The patient presented with fever. CT abdomen showed ileocolic and enterocutaneous fistula with right psoas abscess.
- Drainage under ultrasound guidance was performed 5 times and eventually 2 pigtail drains were put in place.
- The patient was transferred to another hospital for further management.
- At the receiving hospital, a piece of non-woven gauze entangled at the tip of pigtail drain was noted when one of the drain was removed.



Gauze tangled at catheter tip

#### Key Contributing Factor:

Gauze accidentally entangled during insertion of pigtail drain procedure.

#### Recommendations:

1. Keep skin puncture site clear of gauze during skin incision, needle / guide wire / dilator / catheter insertion and exchange procedure.
2. Exercise caution when there is a large amount of oozing of blood or pus during the procedure.

- A patient with diabetes, hypertension and advance dementia was under the care of Community Nursing Service (CNS) for sacral pressure ulcer.
- She was hospitalized for 5 days for poor oral intake. During the hospital stay, the patient's sacral sore was measured 3(L) X 2(W) X 1 (D) cm and was managed with daily wound dressing.
- The patient continued to receive wound care by CNS after discharge. Different wound dressing materials were used to pack the wound at different times.
- On the fourth home visit, it was discovered that an extra piece of dressing, which was not documented in the Clinical Management Sheet, was inside the patient's wound.

### Key Contributing Factor:

Lack of clear documentation on the number of wound packing material packed and removed in wound after the wound dressing procedure.

### Recommendations:

1. Redesign the "Wound assessment Form" to include elements of wound management plan.
2. Design a chop / label to facilitate documentation on the counting of wound packing material.

## Wrong Side Procedure

- A female patient attended Diagnostic Radiology Department for a scheduled ultrasound-guided (USG) Fine Needle Aspiration (FNA) of her **left** breast nodule.
- On arrival, the attending nurse checked the patient's identity and read the referral form indicating the site of FNA: '**L2-3H**'.
- The patient stated that she was going to have FNA on the **right** side and the attending nurse positioned the patient with her **right** breast exposed accordingly.
- The radiologist performed an ultrasound examination on the patient's **right** breast. Unable to identify any lesion at the 2 – 3 O'clock area, he performed FNA targeting the background breast tissue.
- The nurse recognized that a wrong side procedure had been performed after cross checking the request form with the radiographer.
- The error was then explained to the patient and FNA on the left side lesion was performed.

### Key Contributing Factors:

1. Unclear role delineation while conducting the "TIME-OUT" procedure.
2. No verification of the operating side before the procedure.

### Recommendations:

1. Update the "TIME-OUT" procedure guidelines to better define the roles of team members.
2. Revise the "TIME-OUT" checklist to include verification in side-specific procedures.
3. Reinforce training of staff on vigilant adherence to standard of practice.

## Maternal Death

- A pregnant woman at 40 weeks gestation was admitted for past term induction.
- Shortly after delivery, the patient developed cardiac arrest and disseminated intravascular coagulopathy. Despite resuscitation, the patient succumbed.
- A post-mortem examination revealed that the patient had amniotic fluid embolism.

### Concluding Remarks:

1. Amniotic fluid embolism is a rare but known complication of pregnancy.
2. The treatment and care provided to the patient was found to be timely and appropriate.



## Unintended Continuous Steroid Prescription

- A patient, who had underlying end stage renal failure, hypertension, and ischaemic heart disease, was admitted for removal of Tenckhoff catheter. Incidental finding of “acute bronchitis” was diagnosed by the attending doctor.
- The patient was discharged after a brief stay on a regimen of steroid (prednisolone 25mg daily), antibiotics and a number of other medications. Steroid was planned to be prescribed for 6 days, until symptoms settled down.
- The patient returned 8 days after discharge for haemodialysis treatment. The same dose of steroid was prescribed with the other medications until the next follow up, which was 96 days later.
- Two months later, the patient was admitted for severe pneumonia. Despite initial clinical improvement, the patient succumbed 11 days after admission.

### Key Contributing Factors:

1. No “**Single Use / Fixed Period**” was specified for the initial prescription of steroid therapy in Medication Ordering Entry (MOE).
2. No indication for steroid therapy documented in the initial prescription for steroid therapy.
3. No verification mechanism for oral steroid in the MOE carry-forward instruction.

### Recommendation:

Enhance the MOE system to prompt the prescriber to verify whenever “long-term” steroid is prescribed and state the intended duration of the steroid therapy.

## Patient Suicide

In Q1 2014, there were 4 patient suicides involving 3 males and 1 female, aged between 29 and 77. Of the 4 patients, 1 had history of suicidal attempt and had received psychiatric care.

Of the 4 patients, 3 committed suicide by jumping from heights during home leave. Two of them (1 diagnosed with lung cancer; the other chronic medical illness) were being cared for in the general ward and 1 in a psychiatric ward.

The fourth patient, who had underlying stomach cancer, committed suicide by hanging himself with a nylon rope and a plastic chain in the ward bathroom.

### Key Contributing Factors:

1. Underlying medical illness and un-anticipated change in the patient’s mental status.
2. Presence of environmental risks in patient’s bathroom.
3. Ineffective communication between patient’s relative and hospital staff.
4. Ineffective actions to verify whether a patient was found missing during home leave.

### Recommendations:

1. Minimize any potential anchorage for hanging in toilets and bathrooms.
2. Provide education to patient’s relatives in reporting patient’s suicidal or suspected suicidal ideas.
3. Standardize the instructions for handling reports of patients being found missing during home leave.



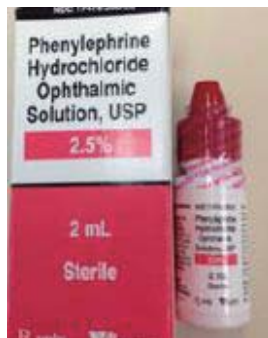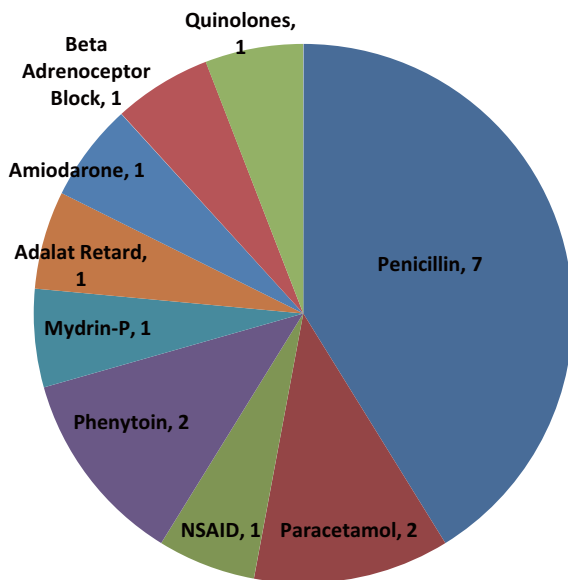
Door beam that patient used for hanging

# SERIOUS UNTOWARD EVENTS Q1 2014

There were 31 SUE cases reported in this quarter, of which 29 were medication errors and 2 patient misidentification. Cases related to medication errors included known drug allergy (17), use of dangerous drugs (4), Insulin (4), Anticoagulants (2), Inotropic agents (1) and others (1).

## Medication Incidents related to Known Drug Allergy (KDA)

### Distribution of Known Drug Allergy in 1Q14



### Case Highlight: Mydrin P eye drops was administered

- A patient with allergy history to Mydrin P eye drops attended a pre-operation assessment clinic before a scheduled cataract operation.
- The case doctor prescribed 3 pre-medication eye drops on a **pre-printed** Medication Administration Record (MAR) by signing on these 3 drugs, deliberately omitting the 4th drug - Gutt. Phenylephrine 2.5% - which was the active ingredient of Mydrin P.
- The MAR was then sent to the Day Surgical Unit.
- On the day of operation, the MAR was faxed to and all 4 drugs were dispensed by the Pharmacy.
- All 4 drugs, including Gutt. Phenylephrine 2.5% were subsequently administered to the patient's left eye as pre-medication.
- The error was noted by another nurse.
- The patient developed mild redness over the left eye and mild numbness over the left face.
- The operation was postponed.

### Key Contributing Factors:

1. Lack of standard good practice on handling un-prescribed drug on the pre-printed MAR.
2. Incorrect assumption of valid prescription without checking for the doctor's signature before drug administration.
3. Lack of easy reference for commonly used eye drops.

### Recommendations:

1. Establish a standardized good practice on handling inappropriate items on the pre-printed MAR.
2. Reinforce the checking of valid prescription before drug dispensing and administration.

Drug	Prescription	Time	Signature
GUTT. NOVAIN 0.4%	Q15min x 3	12:00, 12:30	[Signature]
GUTT. PHENYLEPHRINE 2.5%	Q15min x 3	12:00, 12:15, 12:30	[Not Signed]
GUTT. CYCLOPENTOLATE 1%	Q15min x 3	12:00, 12:15, 12:30	[Signature]
GUTT. TOBRAMYCIN 0.3%	Q15min x 3	12:00, 12:15, 12:30	[Signature]

Pre-printed MAR which the allergy drug was not signed

# LOCAL SHARING

## Sharing on Reported Near Miss Case

A hospital recently reported some near miss events related to Magnetic Resonance Imaging (MRI) safety. The information of whether the patients had implants / devices / object materials and the MR compatibility was not filled in or clearly stated in the request form. The radiographer detected the errors on site before the MRI scanning. Several patients had their appointments deferred for further clarification of MR compatibility while one had the appointment cancelled due to MR incompatibility.

### Case Example

The MRI spine appointment of an outpatient with implanted pacemaker had to be cancelled.

There was discrepancy in the information provided in the MRI request and consent forms for a patient with implanted material.

A patient with an electronic programmable ventriculoperitoneal (VP) shunt was booked for MRI investigation.

Metallic implants were not stated in the MRI Request Form.



Non-MRI compatible devices are **HIGHLY DANGEROUS** as the ferromagnetic property and electric conductivity of MRI can cause device failure, displacement, burn or death which are **PREVENTABLE**.

Examples of Non-MRI compatible devices: pacemakers, vagus nerve stimulators, cochlear implants, deep brain stimulators, implantable cardioverters, magnetic foreign bodies or metal implants such as aneurysm clips and surgical prostheses.

### KEY LEARNING POINTS

1. Check for contraindications when requesting MRI examinations.
2. Use a standardized checklist for safe working in MR environment.
3. Follow MRI safety policy and related guidelines.

*Reference: MRI Safety Manual for HA Hospitals*

## Medication Incident Statistics (Jul – Dec 2013)

No. of Incidents by Severity	
Severity Index	Cases
0	431
1	459
2	85
3	15
4	1
5	0
6	0

Rank	Top 3 Most Common Error Types					
	PRESCRIBING		DISPENSING		ADMINISTRATION	
	In-patient	Out-patient	In-patient	Out-patient	In-patient	Out-patient
1 <sup>st</sup>	Wrong Strength /dosage (30%)	Wrong Patient (47%)	Wrong Drug (50%)	Wrong Strength /dosage (26%)	Dose Omission (21%)	Wrong Dose (18%)
2 <sup>nd</sup>	Wrong Patient (14%)	Wrong Drug (9%)	Wrong Strength/ dosage (20%)	Wrong Patient (23%)	Extra Dose (15%)	Wrong Drug (13%)
3 <sup>rd</sup>	Known Drug Allergy (9%)	Known Drug Allergy (8%)	Wrong Patient/ Wrong Dosage Form (10%)	Wrong Drug (23%)	Wrong Drug (9%)	Dose Omission (13%)

### EDITORIAL BOARD

Editor-in-Chief: Dr Hing Yu SO, SD(Q&S), NTEC

Board Members: Dr Rebecca LAM, CM(PS&RM), HAHO; Dr N C SIN, SD(Q&S), KEC; Dr Tony MAK, SD(Q&S), KWC; Dr Petty LEE, P(CPO), HAHO; Mr Fred CHAN, SM(PS&RM), HAHO; Dr Venus SIU, SM(PS&RM), HAHO;

Ms Katherine PANG, M(PS&RM), HAHO

Advisor: Dr Lawrence LAI, HOQ&S Honorary Senior Advisor

Suggestions or feedback are most welcome. Please email us through HA intranet at address: HO Patient Safety & Risk Management