



RISK ALERT



ISSUE 77 APR 2025

A Risk Management Newsletter for Hospital Authority Healthcare Professionals

IN THIS ISSUE

Sentinel Events (SE) (4Q 2024)

- Wrong Patient/Part
- Retained Instruments/Material
- Inpatient Suicide

Serious Untoward Events (SUE) (4Q 2024)

- Medication Errors

Local Sharing

- Adrenaline for Anaphylaxis Treatment

OPENING MESSAGE

The Importance of Just Culture in Incident Management

A Just Culture is vital in incident management as it fosters transparency, learning, and accountability. By prioritising open reporting over blame, employees feel safe to disclose errors, ensuring incidents are analysed rather than hidden.

This approach shifts focus from individual fault to systemic flaws — like flawed protocols or inadequate training — enabling organisations to address root causes. A Just Culture also balances fairness: it supports those who make honest mistakes while holding reckless behaviour accountable.

This builds trust, encourages collaboration, and drives improvement. In high-risk fields like healthcare or aviation, such a culture prevents repeat failures, enhances safety, and sustains operational resilience. Ultimately, Just Culture transforms incidents into opportunities for growth, safeguarding both people and organisational integrity.

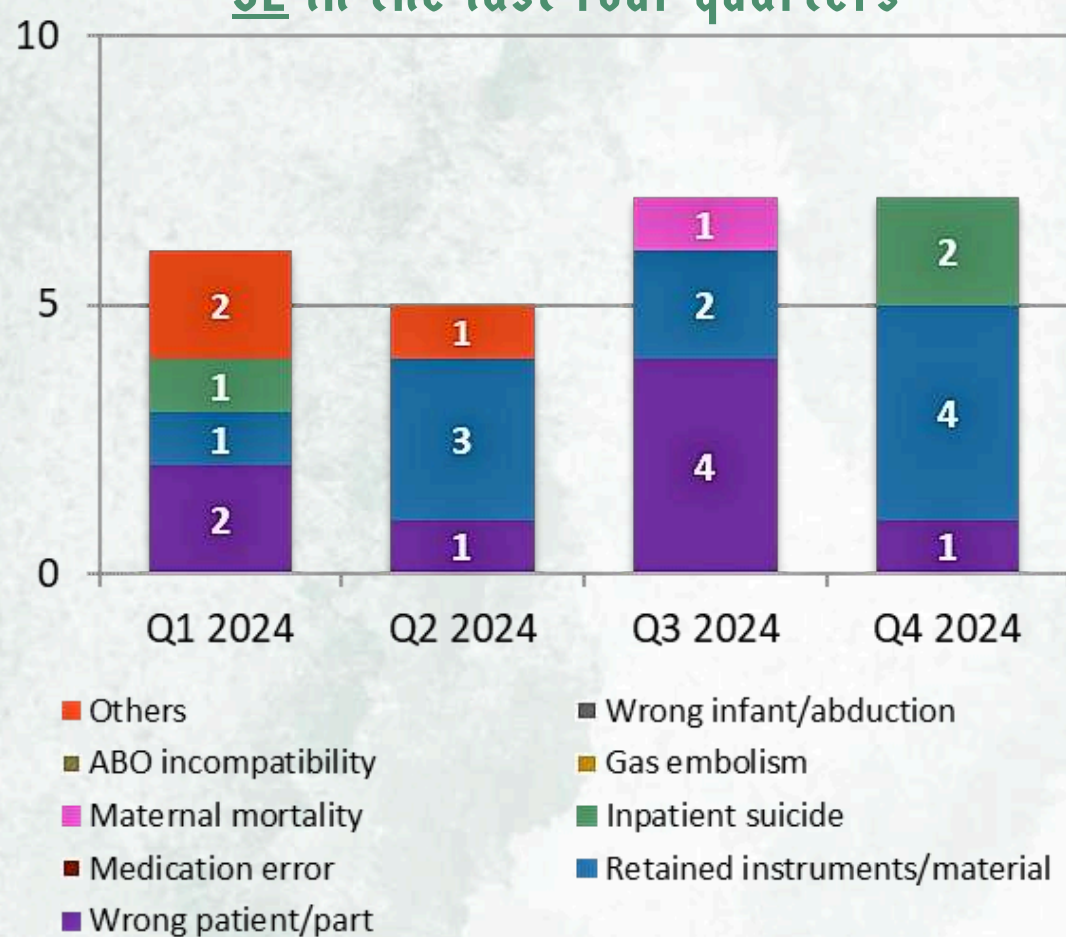


Dr S L LEE

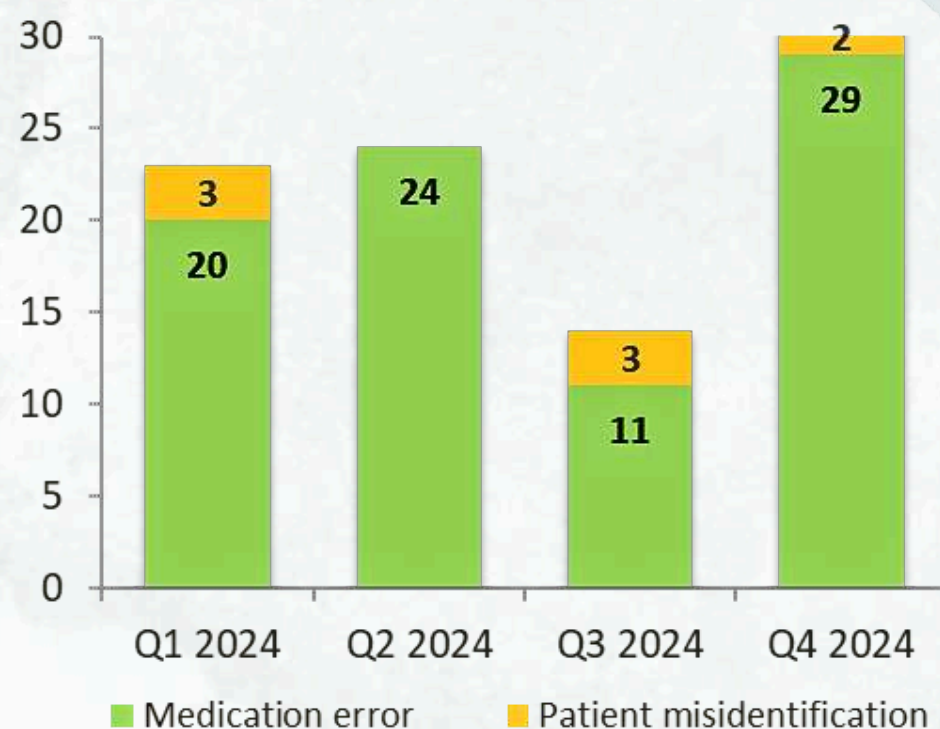**Deputising Service Director(Q&S)
Hong Kong West Cluster**

SE & SUE STATISTICS

Number and distribution of SE in the last four quarters



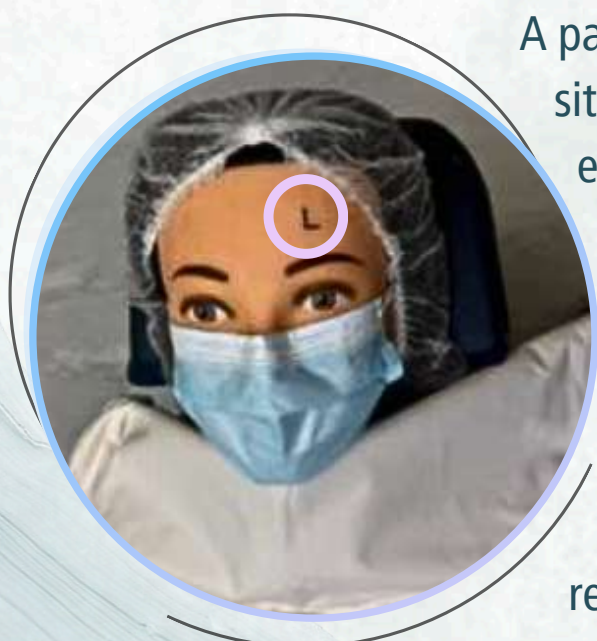Number and distribution of SUE in the last four quarters



SENTINEL EVENTS

Wrong Patient/Body Part

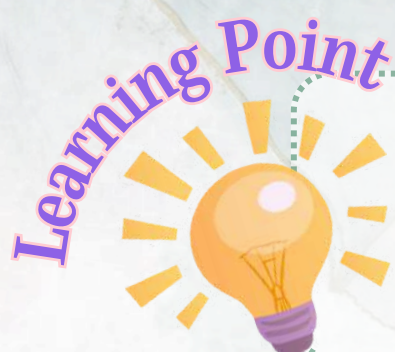
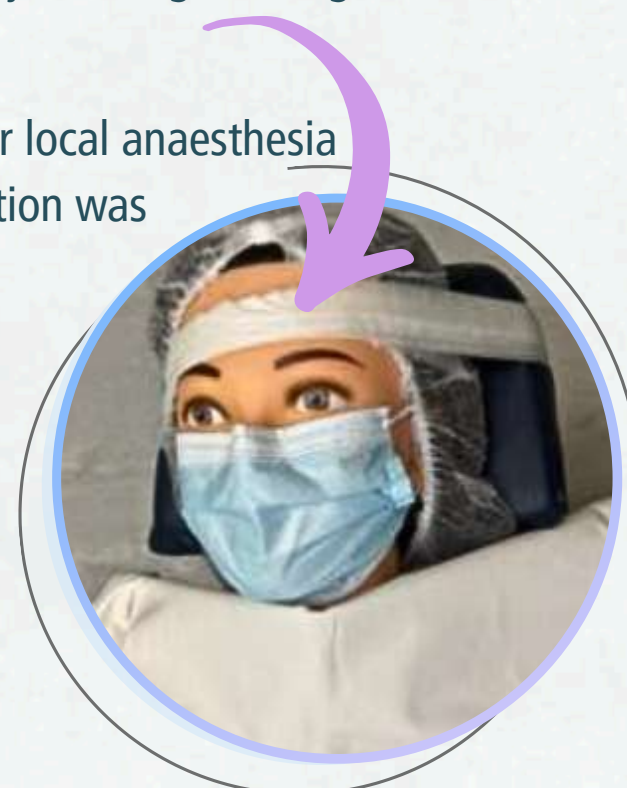
Retrobulbar Local Anaesthesia and Small Incisions Performed on Wrong Eye



A patient was scheduled for **LEFT** eye cataract surgery. Following the completion of site marking on the patient's **LEFT** forehead and the "SIGN IN" process, the patient exhibited involuntary movements. To stabilise the patient's head, a micropore tape was applied to the patient's head, unintentionally covering the surgical site marking.

Despite the "TIME OUT" procedure, retrobulbar local anaesthesia was mistakenly administered and skin preparation was performed to the patient's **RIGHT** eye without re-verifying the surgical site.

The procedure commenced with two incisions (<0.5 mm) made in the **RIGHT** eye. Upon recognition that the local anaesthesia had been administered to the wrong side, the operation was promptly aborted. The incisions were closed with stromal hydration, without the need for sutures. The patient experienced no further adverse effects.



- Ensure visibility of surgical site marking to facilitate surgical team's verification of the laterality
- Perform "TIME OUT" procedure and document the standardised surgical safety checklist just before anaesthesia and incision

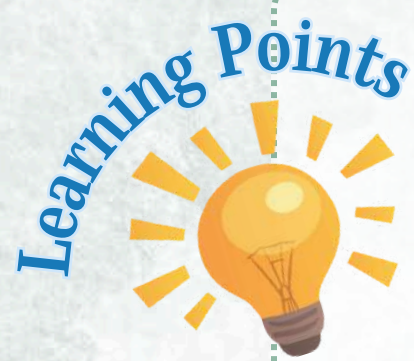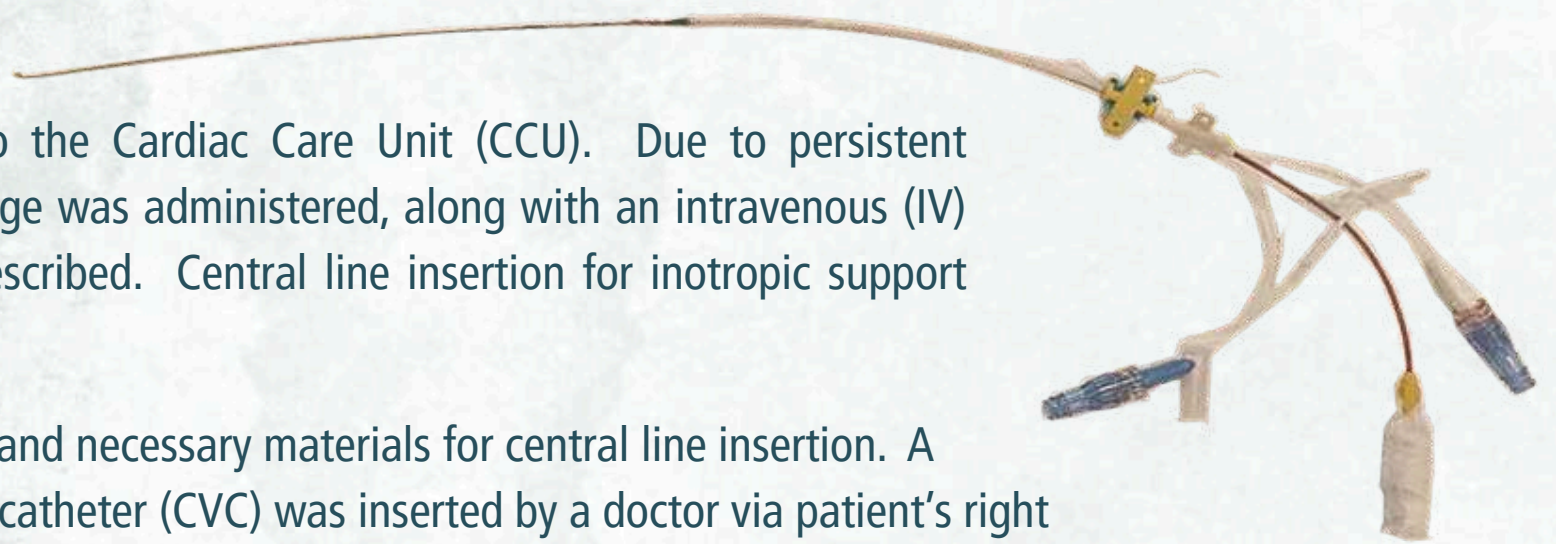
Retained Material

Guide Wire


A patient was admitted to the Cardiac Care Unit (CCU). Due to persistent hypotension, a fluid challenge was administered, along with an intravenous (IV) Dopamine infusion was prescribed. Central line insertion for inotropic support was decided.

Nurses prepared the trolley and necessary materials for central line insertion. A triple lumen central venous catheter (CVC) was inserted by a doctor via patient's right femoral vein. The doctor flushed all three lumens with 0.9% Sodium Chloride solution to assess patency, revealing that the distal lumen did not yield any blood, while the proximal and middle lumens were patent. The concern of potential blockage was raised and another 0.9% Sodium Chloride flush was applied to distal lumen again. Since the other two lumens were patent, the doctor instructed to clamp the distal lumen, and Dopamine infusion was administered through the remaining lumens. The distal lumen was then covered by gauze.

A **guide wire** inside the distal port of the central line was noted during CVC removal in the patient.



- Implement voice command with response for procedures requiring guide wire technique to prevent error
- Enhance speak-up culture and reinforce clarification of queries

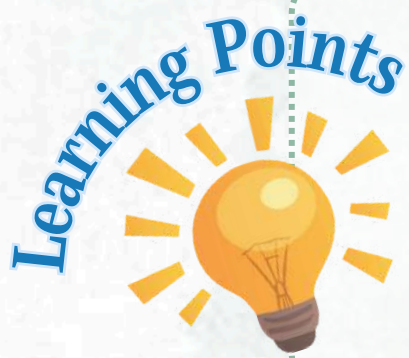
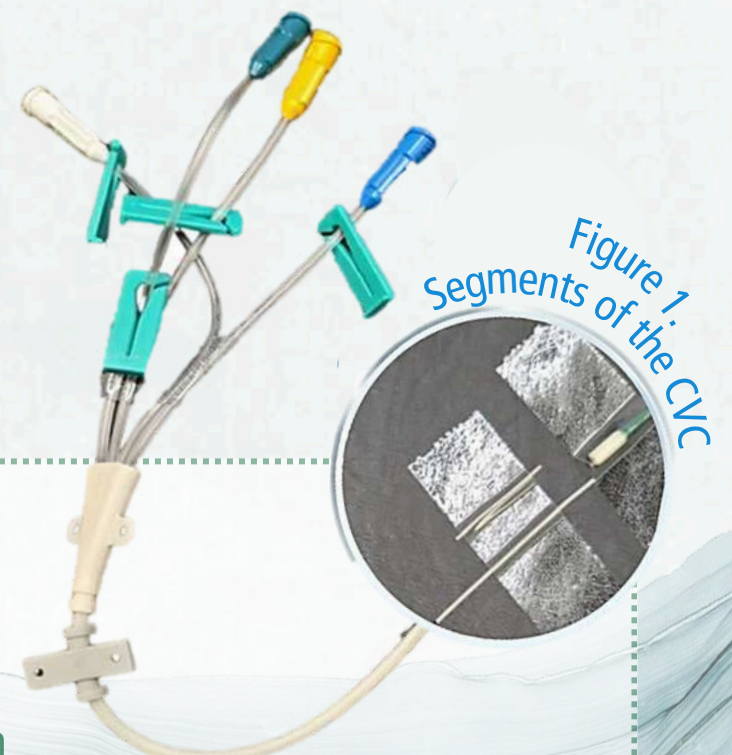
Segments of CVC Inner Lumen

A patient with a history of complex congenital heart disease was admitted for a single-stage Fontan operation. On the day of the operation, a 4-lumen CVC was inserted into her left subclavian vein and anchored.

During the operation, the surgeon observed that the surgical field over the patient's left superior vena cava was obscured by the tip of CVC. The tip of the CVC was cut and kept for further completeness checks. The operation was completed uneventfully.

The catheter was removed post-operatively, and the integrity check could not identify two dislodged inner catheter segments. Post-operative chest X-ray later revealed radiopaque lines, and the retained two tiny inner catheter segments of the CVC (Figure 1) were retrieved by endovascular procedure.



- Avoid cutting the tip of such specific design of CVCs, as this may result in unexpected dislodgement of tube segments
- Formulate a standardised practice to manage situation whenever part of CVC obstructs/obscures the surgical field intra-operatively

Retained Material

Suture Needle

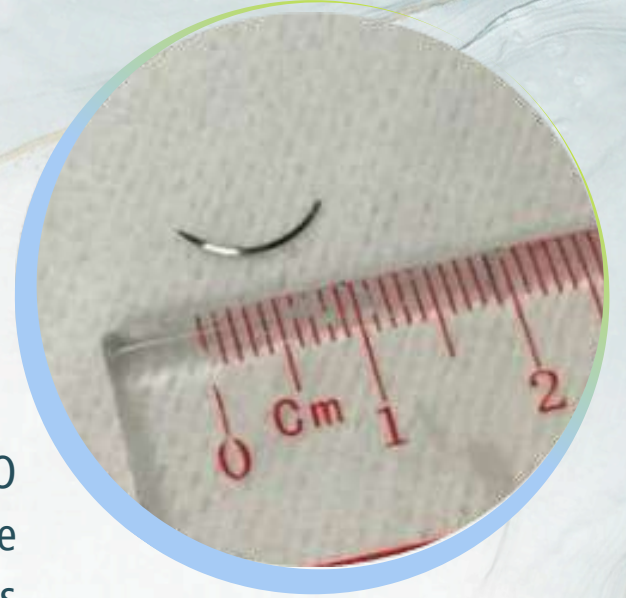
An obese patient was admitted for right pleural effusion. Four attempts for chest drain insertion were made, but all were unsuccessful.

During the second attempt, a 4-0 Dermalon suture needle failed to pierce the chest wall. The case doctor removed the needle from its rear end using a needle holder but did not check the needle's integrity.

A 3-0 Dermalon suture was requested, but the nurses mistakenly provided 4-0 Dermalon packs. A total of three additional Dermalon packs were given before the doctor proceeded to anchor the chest drain. Aspiration from the chest drain was absent, so the drain and sutures were removed.

The two-hour procedure involved three nurses, with inadequate communication regarding the number of suture packs used. Pleural tapping was ultimately performed as an alternative.

The next day, a retained foreign body (the suture needle) was identified on a follow-up X-ray and successfully retrieved.

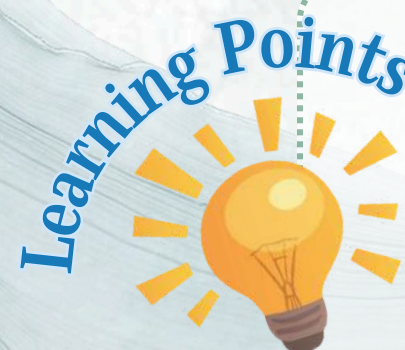
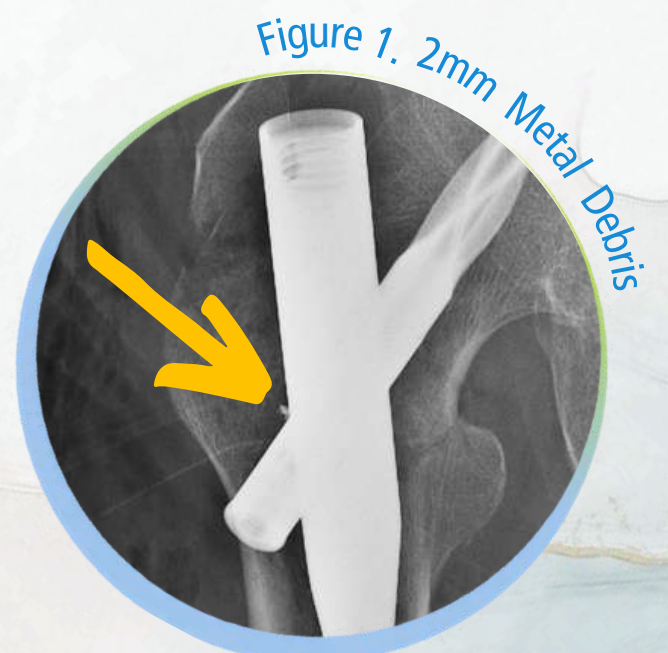


- **Instrument Integrity Checks:** Perform stringent checks of needle integrity after removal from patients
- **"SIGN OUT" Process:** Conduct joint verification of needle integrity and count during the "SIGN OUT" process by doctors and nurses involved in the procedure
- **Seniors' Assistance:** Junior doctors should seek seniors' assistance when encountering difficulties
- **SBAR Communication:** Implement structured communication for clinical handover using SBAR (Situation, Background, Assessment and Recommendation)

Metal Debris

A patient was admitted for intertrochanteric fracture of right hip. A closed reduction and fixation of the patient's right proximal femur with Proximal Femoral Nail Antirotation (PFNA) was performed. A post-operative X-ray confirmed the implant in situ.

The patient was transferred to another hospital three days later. On admission, the post-operative X-ray showed a 2mm metal debris (Figure 1) on the proximal femoral nail near the insertion of the PFNA blade and suspected detachment of the PFNA blade implant. The patient opted for conservative management.



- Strengthen staff alertness to the possibility of debris detachment from PFNA blade
- During intraoperative X-ray screening of fracture fixation cases:
 - Check the quality of reduction and fixation
 - Assess the implant position
 - Monitor the soft tissue condition around the fracture site and implant

In-Patient Suicide

Case 1

A patient was admitted for a scheduled operation on a suspected infected right knee, showed no abnormal or depressive behavior before admission. A suicide assessment was conducted, and no risks were identified. The patient complained of increasing right knee pain and swelling. Panadol was prescribed.

A plastic bag was left at the patient's request during visiting hours. On a routine midnight ward round, the patient was observed sleeping. Shortly afterwards, the patient was found unresponsive with her head covered by a blanket. Upon uncovering her, the patient was found with a plastic bag over her head and a charger cable around her neck. The patient succumbed despite resuscitation.

Case 2

A patient with history of depressed mood and chronic bone pain, presented to Accident and Emergency Department (AED) expressing suicidal ideation and requesting euthanasia. She was diagnosed with severe elderly depression by a psychiatric liaison nurse and admitted to a medical ward for blood pressure control. The patient was assigned to a bed close to the nursing station due to high risk of suicide. Suicidal precautions were implemented, including hourly vital signs monitoring and mood assessments.

At midnight, the patient was discovered attempting suicide by suffocation using a scarf, a patch, and fragments of a compressed plastic bag (reshaped and remoulded into small beads) to block both nostrils (Figure 1). Cardiopulmonary resuscitation (CPR) was initiated and the patient regained spontaneous circulation. However, the patient subsequently passed away.

- Remind staff and patient relatives about the importance of removing nearby dangerous items
- Evaluate the patients' pain level and provide effective pain management as part of suicide prevention in inpatient care

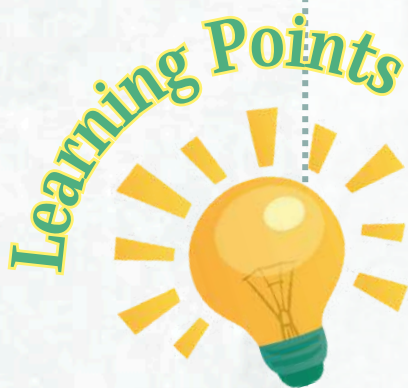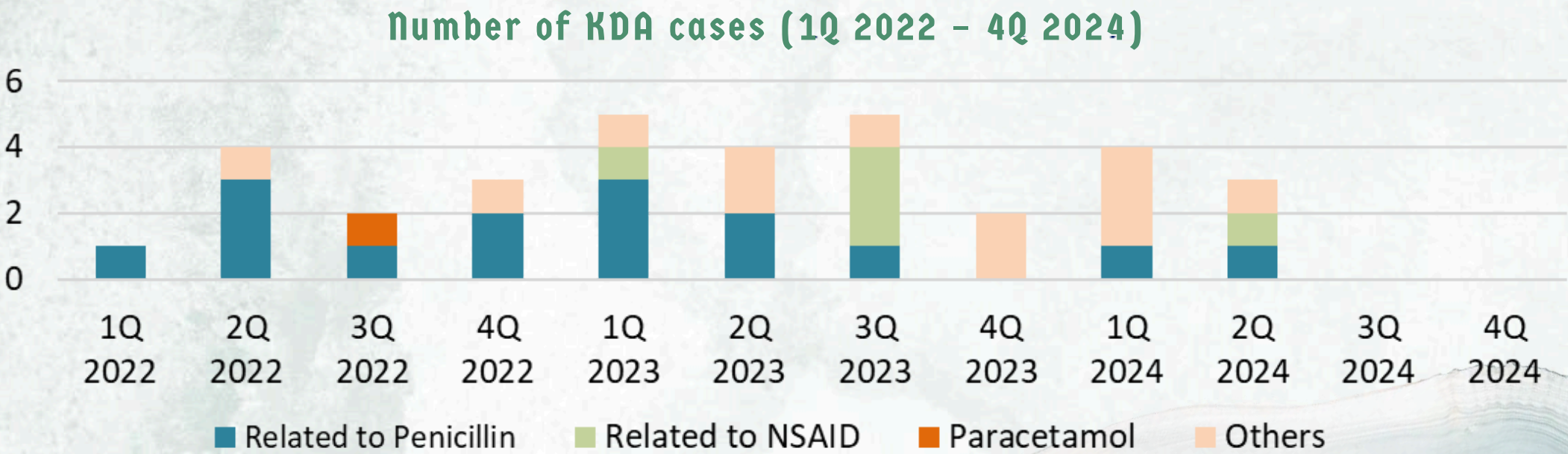


Figure 1.
Compressed plastic bag fragments



SERIOUS UNTOWARD EVENTS

Of the 31 SUE cases reported in 4Q 2024, 29 cases were related to medication errors, including anticoagulants (6), chemotherapy agents (1), dangerous drugs (5), vasopressors and inotropes (4), concentrated electrolytes (1), insulin (3) and others (9).



*No KDA case from 3Q – 4Q 2024

Medication Errors

Case 1 *Insulin infusion was not adjusted per blood glucose result*

Doctor adjusted a diabetic ketoacidosis patient’s insulin regimen:

- Stat dose of 36 units of subcutaneous (SC) Novomix 30 injection, and
- To stop the IV Actrapid HM infusion 2 hours after the SC injection, with adjustments to the infusion rate per the sliding scale protocol.

Nurses administered the stat dose of SC Novomix 30 injection but failed to adjust the IV Actrapid infusion rate as instructed. The patient remained stable throughout.

Case 2 *Extra dose of Insulin Neutral Human (Actrapid HM) continuous infusion was given*

- An **adjustable insulin infusion** and **hourly glucose monitoring** were prescribed to manage hyperglycemia.
- The nurse continued insulin infusion at a constant rate of 4ml/hour, unaware of the hourly glucose monitoring and did not check the glucose level. The patient subsequently developed hypoglycemia.



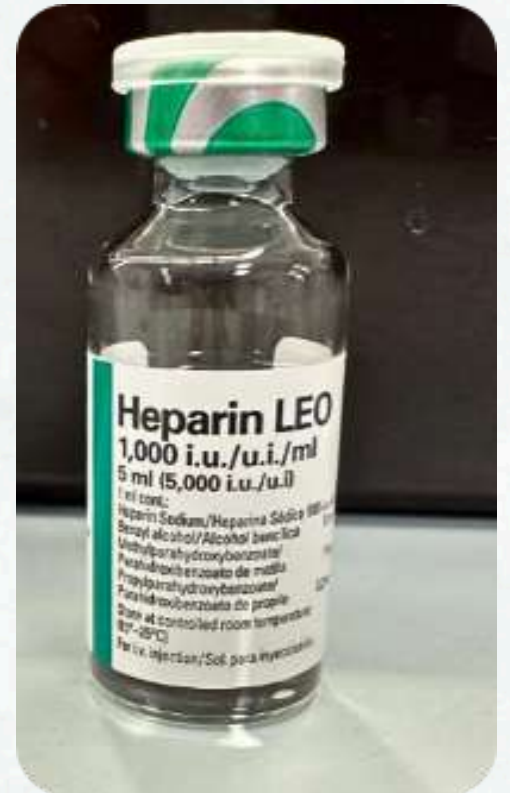- Ensure consistent and clear documentation in the “Test Strip Blood Glucose Monitoring Form”, including monitoring frequency and recording insulin infusion dosages administered
- Flag the patients on intravenous high alert medication (e.g. insulin) for close monitoring and timely care



Medication Errors

Heparin 20000 units instead of 4000 units was administered intravenously to a patient

- A patient was admitted for acute right upper limb ischaemia.
- Heparin regimen was prescribed as **4000 units** IV bolus followed by continuous infusion of 10000 units of Heparin in 100ml Normal Saline at a rate of 6ml/hour.
- The nurse misinterpreted the drug label, perceiving each vial to contain 1000 units in 5ml, when in fact each vial contained 1000 units per ml (5000 units per vial).
- As a result, the nurse used four vials (20,000 units total) to prepare the IV bolus dose.
- This error was not identified during counterchecking by another nurse and the medication was administered to the patient. The patient's condition remained stable.



Reinforce proper independent double-checking and going through the five rights independently with "Point & Read" technique before administration

How to read Drug Description on Inpatient Dispensing Labels?

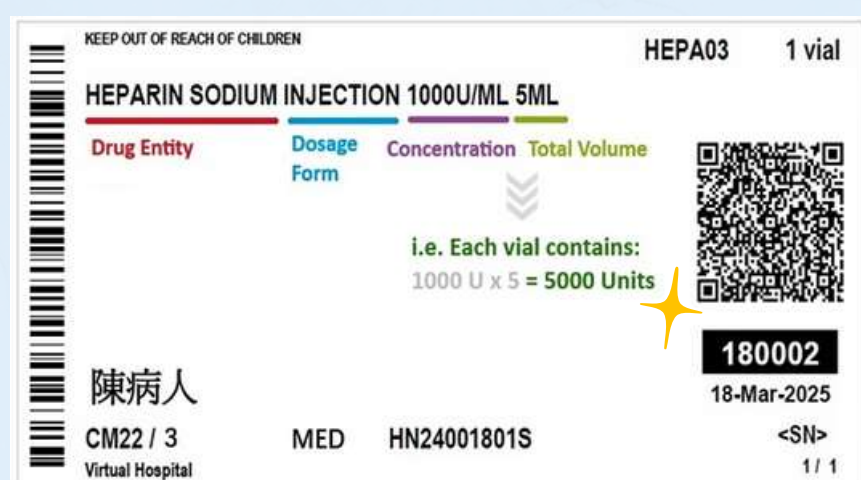


In principle, **DRUG DESCRIPTION** printed on inpatient dispensing labels contains:

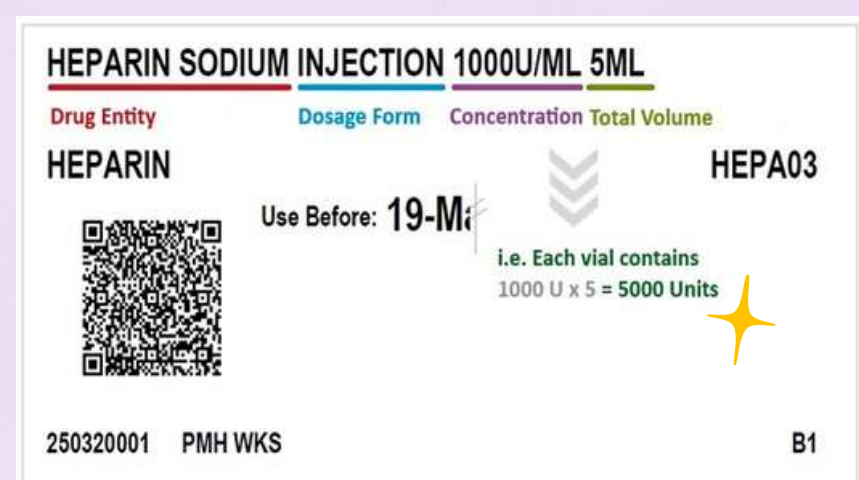
- **Drug Entity**
– drug name +/- its salt, e.g., Heparin Sodium
- **Dosage Form**
– e.g., injection
- **Concentration or Strength**
– e.g., 1000U/ML
- **Total Volume or Pack Size**
– amount of substance in the container, e.g. 5ML

There are **two types** of inpatient dispensing labels, as follows:

Individual Patient Dispensing Label



Ward Stock Prepacking Label

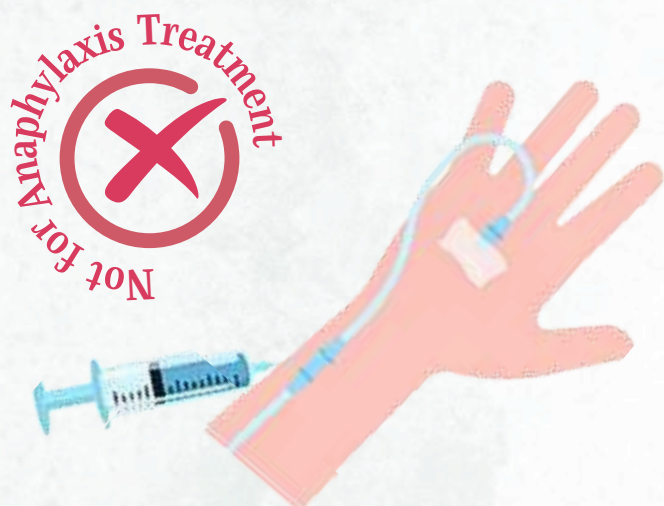

- **Variations on drug description** do exist among different drug products.
- It is essential to **exercise professional judgment** when reading the label.
- Consult your **hospital pharmacist** when in doubt.

Written in collaboration with CPO's
Pharmacy Informatics & Automation Technology Section

In 4Q 2024, there were three incidents occurred where Adrenaline 1:1000 was mistakenly administered via the **IV route** instead of the intended **IM/SC** route for anaphylaxis patients.

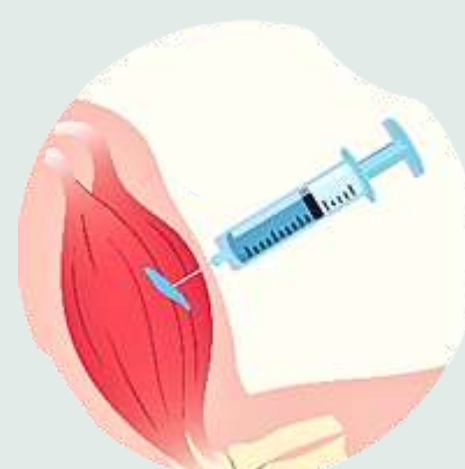Types of Injections:



Intravenous (IV)

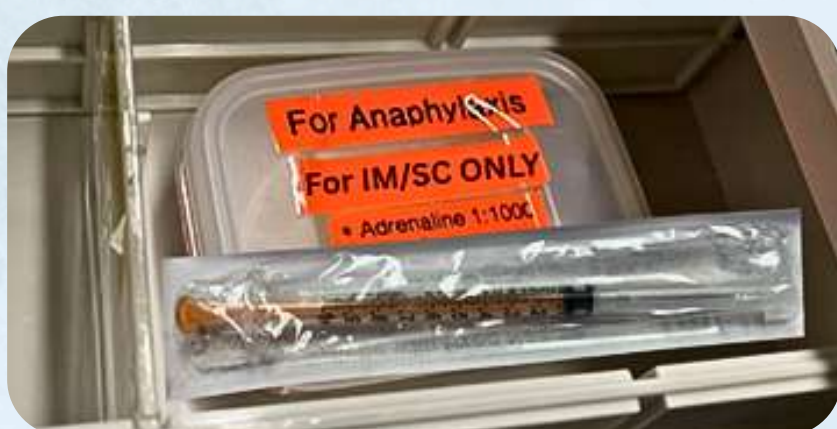

Subcutaneous (SC)

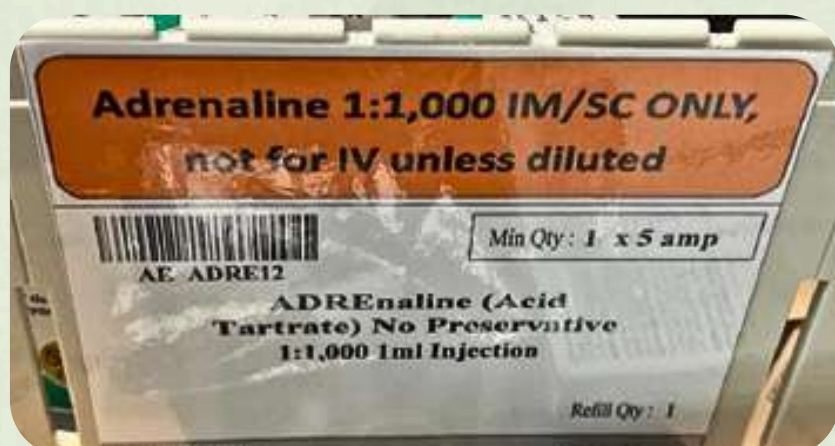

Intramuscular (IM)

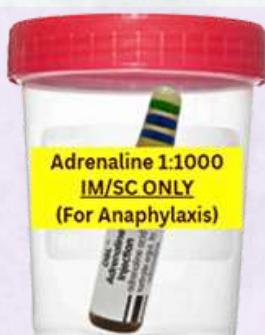- 1 Prepare an anaphylaxis kit with clear warning sign and 1ml syringe for IM/SC injections



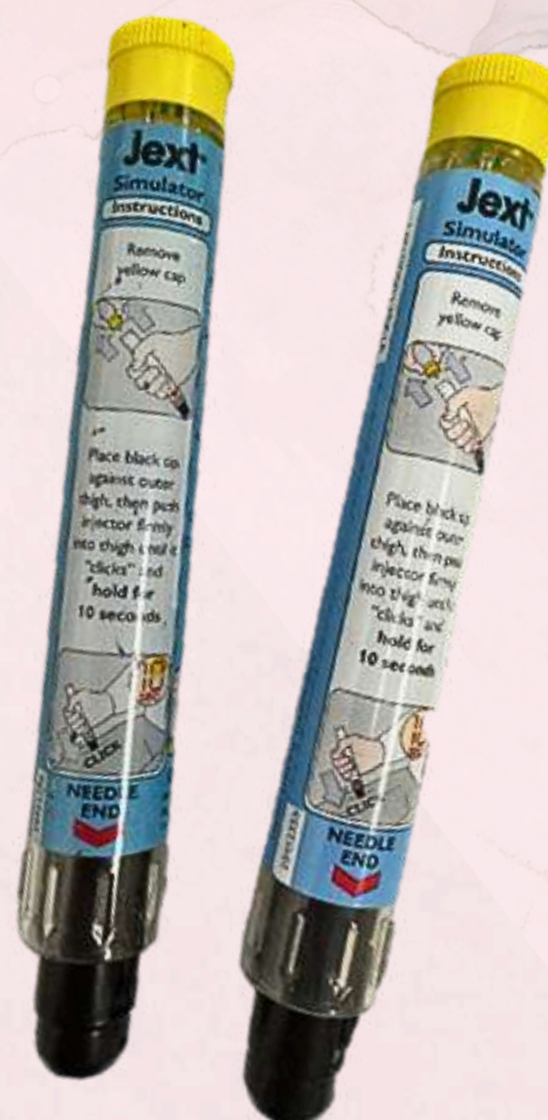- 2 Put up an auxiliary label highlighting the IM/SC route of administration for Adrenaline 1:1000 injection



- 3 Put an alert sign on the container where Adrenaline 1:1000 injections are stored



- 4 Place **Adrenaline autoinjectors***, which are prefilled and designed for IM use, in AEDs



*Not for patients under 15 kg

EDITORIAL BOARD

Editor-in-Chief: Dr W M CHEUNG, CM(PS&RM), HAHO

Members: Dr Sara HO, SD(Q&S), HKEC; Dr Linda YU, SD(Q&S), NTEC; Mr Brian LEUNG, P(CPO), HAHO; Dr Nicole CHAU, SM(PS&RM), HAHO;

Ms Winnie WONG, M(PS&RM), HAHO; Ms Moon CHAN, M(PS&RM), HAHO, Ms S Y CHIU, M(PS&RM), HAHO.

Suggestion or feedback is most welcome. Please email us through HA intranet at address: HO Patient Safety & Risk Management