



RISK ALERT



ISSUE 62 JUL 2021

A Risk Management Newsletter for Hospital Authority Healthcare Professionals

IN THIS ISSUE

★ Sentinel Events (SEs) (Q1 2021)

* Retained Instruments / Material * Wrong Patient / Part * Inpatient Suicide

★ Serious Untoward Events (SUEs) (Q1 2021)

Opening Message

Cognitive Bias and Medical Error

“The fool doth think he is wise, but the wise man knows himself to be a fool” - Shakespeare

An important concept in understanding error is that of cognitive bias, and the influence this can have on our decision-making. Cognitive biases are cognitive short cuts used to aid our decision-making. It can be thought of as a cognitive guideline that one subconsciously applies to a complex situation to make decision-making easier and more efficient. It has been recognized within the medical community since the 1970s but research has been sporadic and largely in fields outside of medicine, such as the military, economics and business. It is now becoming increasingly apparent that significant diagnostic error can result from cognitive bias.

An increasingly established framework for understanding the decision-making process is the dual process theory¹. This theory considers our thought process as a type 1 or type 2 process, with each pathway characterized by their own important attributes. Type 1 thinking is a fast, intuitive, pattern recognition driven method of problem solving, which places a low cognitive burden on the user, and allows one to make fast and accurate decisions rapidly. In contrast, type 2 thinking is a slower more methodical and thoughtful process. Type 2 thinking may place a higher cognitive strain on the user but allows them to appraise data more critically and look beyond patterns, and may potentially be more suitable for complex problem solving. Current opinion among psychologists is that we spend about 95% of our time in type 1 thinking. Although very efficient and time effective, cognitive bias and resulting error is thought to be more likely to occur during type 1 processing.

The following are some suggested rules for good decision-making, adapted from the BMJ.²

- Slow down.
- Be aware of base rates.
- Consider whether data are truly relevant, rather than just salient.
- Seek reasons why your decisions may be wrong and entertain alternative hypotheses.
- Ask questions that would disprove, rather than confirm your current hypothesis.
- Remember that you are wrong more often than you think.

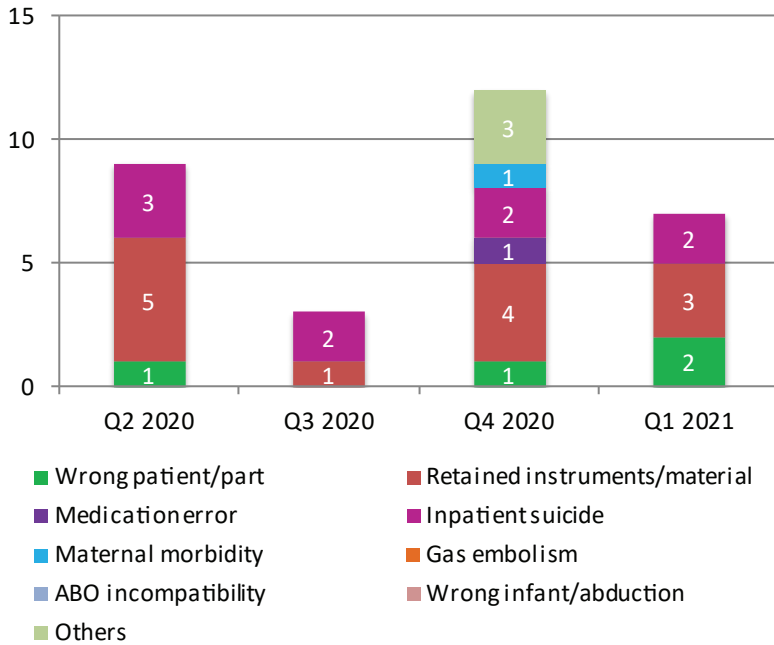
Dr Chi-Keung CHING
Deputising Service Director (Quality & Safety)
Kowloon East Cluster

1. Kahneman D. *Thinking, Fast and Slow*. 1st ed. New York: Farrar, Straus and Giroux; 2011

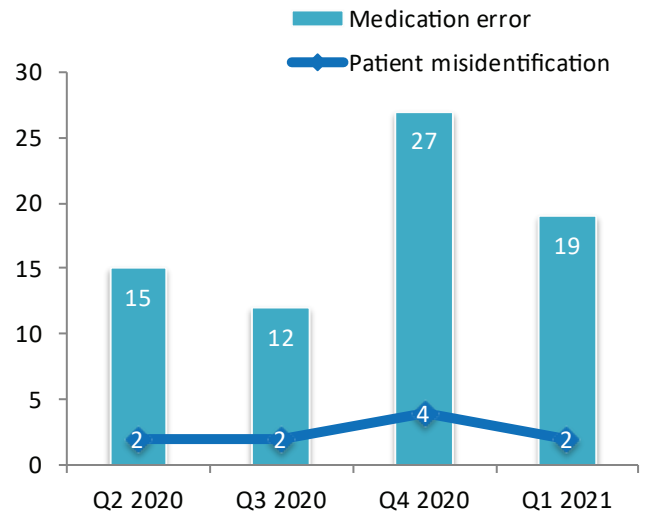
2. Klein JG, Kahneman D, Slovic P et al. Five pitfalls in decisions about diagnosis and prescribing. *BMJ* 2005; 330: 781-3

SE & SUE Statistics

Distribution of SE in the last four quarters



Distribution of SUE in the last four quarters



Sentinel Events

Wrong Patient / Part

Retrobulbar block performed on the incorrect eye

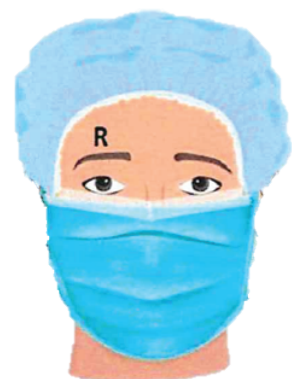- Doctor performed skin marking for the **RIGHT** eye in elective cataract extraction, after checking consent and confirming with the patient.
- Doctor and nurse conducted “TIME OUT” procedure at the patient’s **LEFT** side.
- Nurse then went to the head of the bed to assist, while doctor remained at patient’s **LEFT** side to perform retrobulbar block.
- Doctor immediately realized that the injection was administered to the incorrect **LEFT** eye.
- Upon assessment, patient was stable and there was no anaesthesia-related complication.
- Condition was explained to the patient who agreed to proceed with surgery. **RIGHT** eye cataract extraction was performed uneventfully under **RIGHT** retrobulbar block.

Why did it happen?

- Staff was not vigilant in checking laterality
- Lapse of attention and distraction during the procedure

What can we do to prevent?

Add a pause immediately before injection to reconfirm the marked operating site



Laterality marked above patient’s **RIGHT** eyebrow

Veno-arterial (VA) cannulas reversely connected to extracorporeal membrane oxygenation (ECMO) system

- VA-ECMO to left femoral artery and vein was planned for a patient, who was successfully resuscitated from a cardiac arrest.
- During ECMO preparation, patient became agitated and struggled. Doctor had to put aside the cannula connection to the ECMO machine and stabilise the patient.
- After connection to the ECMO machine eventually, patient's blood pressure was persistently low.
- Intensive Care Unit (ICU) doctor was consulted. The VA cannulas were found reversely connected.
- After rectification, patient proceeded with percutaneous coronary intervention uneventfully and was transferred to ICU for further management.

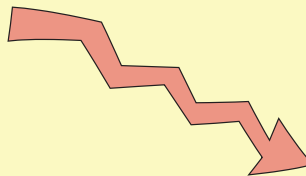
Why did it happen?

- Lapse of concentration – The patient was agitated during the ECMO preparation. Doctor had to pause the connection of the V and A cannulas to the ECMO machine and stabilise the patient.
- The patient was in cardiogenic shock at the moment of cannulation and connection to the ECMO machine. The colour of the blood from the femoral artery might not appear as 'red' as it should be.

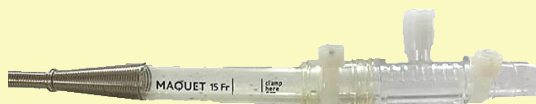
What can we do to prevent?

- Remove the **blue cap of the venous sheath** and the **red cap of the arterial sheath** only during the last step of connection to the **drainage** and **return** tubings of the ECMO machine respectively.
- Enhance checking for correct anatomical sites of cannulation and correct blood flow direction, immediately after connection to the ECMO machine, with independent checking by the doctors responsible for the cannulation procedure.

Before removing cap



No colour differentiation
after removing cap



Remove the **blue/red** caps **ONLY** immediately before connecting to **drainage/return** tubings

Ribbon gauze

- A patient underwent emergency incision and drainage under general anesthesia for perianal abscess. Two ribbon gauzes were packed into the wound.
- In the next morning round, a doctor removed one ribbon gauze and informed the ward nurse to remove the remaining one.
- Ward nurses could not find the remaining gauze in the wound and presumed it had fallen off somewhere. Case nurse then documented that the previously packed ribbon gauzes had been completely removed and only one new ribbon gauze was packed.
- Patient was discharged after the wound dressing with a referral to General Outpatient Clinic (GOPC). Both treatment sheet and Nursing Discharge Summary recorded only one ribbon gauze in the wound, for daily dressing.
- Four days later, GOPC nurse retrieved two ribbon gauzes from the wound, one of which was compatible with the one packed intra-operatively. The ribbon gauze had been retained in patient's wound for five days. Patient's wound was otherwise well.

Why did it happen?

- Not easy to spot the retained ribbon gauze in a small wound opening with deep tunnel
- Staff was unfamiliar with the reporting mechanism and did not report timely on the discrepancy of gauze count
- Incorrect documentation of "complete removal of gauze" in the wound packing record due to false reassurance that no gauze was found during wound assessment

What can we do to prevent?

- Promulgate good practice of leaving distal end of the dressing material outside the wound for easy visualisation and retrieval
- Reinforce nurses to report if there is discrepancy in the dressing material count
- Reinforce correct documentation of gauze count (actual number of gauze removed and packed) and essential information of packed items (material, number and length) on wound packing record

Guide Wire

- A patient was admitted to surgical ward due to acute abdominal pain.
- Upon admission, patient developed septic shock.
- Central venous catheter (CVC) insertion was performed by a doctor, assisted by a nurse and a supporting staff.
- In the midst of the procedure, the nurse discarded suturing sharps and mistook them as the guide wire. The nurse hence incorrectly confirmed the doctor that the guide wire had been removed.
- After the procedure, chest X-ray (CXR) revealed the guide wire, but no other complication.
- The retained guide wire was removed at bedside.

Why did it happen?


- The process of "SIGN OUT" was done without visual confirmation

What can we do to prevent?

- Reinforce the importance of stringent checking with visual and verbal confirmation of the removed guide wire
- Revisit CVC insertion procedural workflow e.g. to discard sharp and guide wire after completing "SIGN OUT"

Detached segment of guide wire

- A patient with end-stage renal failure on haemodialysis (HD) underwent right Permcath insertion and removal of temporary left internal jugular line. Due to calcification and narrowing of the right internal jugular vein (IJV), two different guide wires – J-shaped and straight tips were deployed but both failed to advance beyond 8 cm despite multiple attempts. Procedure was abandoned. The integrity of the two guide wires were checked and documented. CXR did not detect any abnormality.
- Ultrasound-guided right Permcath insertion was thus scheduled for the patient a few days later. During the procedure, radiologist encountered similar difficulties and performed Permcath insertion on left IJV instead. CXR showed left Permcath in-situ, with no pneumothorax. Patient was discharged home and had HD in subsequent days.
- In the three weeks following Permcath insertion, patient had recurrent left neck puncture site bleeding. Computed tomography (CT) of neck and thorax revealed a retained foreign body within the right IJV.
- Retrospective review showed that the detached segment of the guide wire was present in the first set of post-procedural CXR.



Why did it happen?

- Lack of staff awareness of the risk of coating detachment of hydrophilic guide wire during manipulation
- Tapering of right IJV near base of neck with dystrophic calcification and stenosis led to difficult cannulation and interpretation of post-procedural CXR and ultrasound

What can we do?

- Enhance staff awareness on the risk of coating detachment from hydrophilic guide wire and remind staff to remove the metal needle before withdrawing the guide wire
- Keep a high index of suspicion of possible retained foreign body in all attempted areas when reviewing post-procedural X-Ray in difficult cannulation cases


Hydrophilic guide wire precautions

Key information:

1. There is a layer of special coating on the surface of the hydrophilic guide wire.
2. This special coating can be potentially peeled off by the sharp edge of a metallic needle and retained inside the vessel or body.
3. The risk of detachment of hydrophilic coating is even higher if the guide wire is kinked when attempting to withdraw through a metallic needle.

Recommendations:

1. Consider using other guide wires without coating or with Polytetrafluoroethylene (PTFE) coating, which has much lower risk of detachment, if possible.
2. Avoid passing the hydrophilic guide wire through a metallic needle whenever possible. In case hydrophilic guide wire is used to pass through a metallic needle, please take extreme care on it.
3. Consider replacing the metallic needle by a plastic sheath, e.g. angio-catheter before using the hydrophilic guide wire.
4. Stop pulling the guide wire if any resistance is encountered during withdrawal of the hydrophilic guide wire over a needle or sheath. Always withdraw the needle or sheath over the guide wire before pulling the guide wire out.
5. Integrity of the hydrophilic guide wire should always be carefully checked after the procedure.



Inpatient Suicide

In Q1 2021, two in-patients (aged 32 and 68) had committed suicide, one by stabbing with knife and one by jumping from height after found missing.

Case One

- A patient was admitted for suspected haematological malignancy. He had no suicidal ideation nor self-harm behaviour on admission. Upon subsequent diagnosis of acute myeloid leukaemia, he remained calm and showed acceptance of his disease.
- Patient was later transferred to another ward for chemotherapy. A staff noticed that he kept a knife in the bedside locker and advised him to change to a blunt or plastic knife for cutting fruits.
- A few days later, patient developed shortness of breath requiring oxygen therapy. He expressed concern about his deteriorating illness to his case doctor. He remained calm and stable when doctor gave him supportive counselling and reassurance. Doctor consulted clinical psychologist afterwards.
- In the same afternoon, patient's condition worsened, requiring 100% oxygen via non-rebreathing mask.
- Upon assessment, doctor found that his bed sheet was soaked with blood. Multiple stab wounds were noted over patient's anterior chest wall, with another actively bleeding laceration in lower anterior neck. A knife was found under his right flank.
- Resuscitation was activated but patient succumbed around one hour later.

Conclusion

- Patient's major illness and rapid deterioration might have contributed to his act of self-harm.
- The clinical observation and management provided by the clinical team were appropriate and reasonable. The assessment of patient's psychosocial status and suicidal risk was conducted properly.

Case Two

- A patient with history of alcoholic dependence, attended Accident and Emergency Department (AED) for alcohol withdrawal symptoms. The patient was alert and emotionally calm upon admission.
- In view of patient's psychiatric history, emotional status was assessed every two hours. At night, patient expressed his wish to be discharged.
- The next morning, patient was found missing at 08:30. Local search was conducted but in vain. Ward staff and patient's father failed to contact the patient. Hospital security was notified.
- According to CCTV footage, patient had left the hospital earlier in the morning after leaving an incorrect ward information with a security guard and expressing his intention to leave the hospital premise to smoke.
- At 08:35, the missing patient was found lying on the ground in a roof-top garden at a nearby Light Rail Transit station.
- Despite resuscitation, the patient was certified dead in AED.

Conclusion

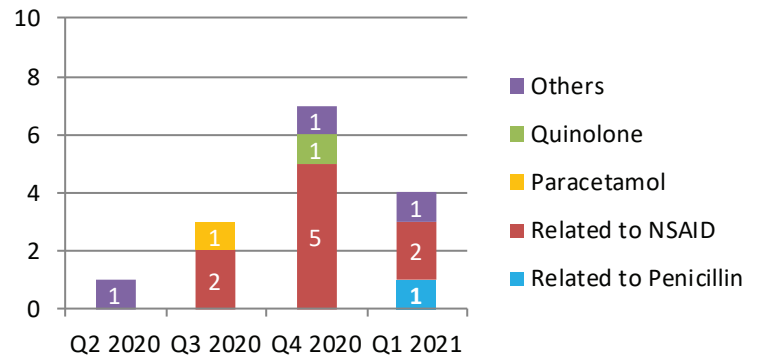
- Apart from having alcohol withdrawal symptoms, patient was all along emotionally calm and stable during hospitalisation.
- After the incident, the Hospital Security team will report all patients in hospital pajamas leaving hospital premise to duty Hospital Foreman immediately for necessary follow-up actions.



Serious Untoward Events

Of the 21 SUE cases reported in Q1 2021, 2 cases were due to patient misidentification and 19 cases were due to medication errors – known drug allergy (KDA) [4], dangerous drug [4], anticoagulant [3], insulin [1], concentrated electrolyte [2] and others [5]. There was no allergic reaction in the known drug allergy cases.

Known Allergy	Allergen prescribed
Penicillin	Augmentin
Meloxicam	Ketorolac
Arcoxia	Aspirin
Metoclopramide	Metoclopramide



Number of KDA cases in the last four quarters

Medication Error

Phenytoin

- A 34 month-old child attended A&E for fever and vomiting and developed convulsion while awaiting transfer to a paediatric ward in another hospital.
- After two intravenous (IV) doses of diazepam, Doctor B consulted paediatric Doctor C who suggested a loading dose of IV phenytoin (dilantin). Doctor B used the Paediatric Resuscitation Calculator to calculate the phenytoin dosage. However, the administration rate was not mentioned in the calculator.
- Doctor B later found the term 'IV bolus and infusion' for phenytoin in a local guideline and perceived it could be given by IV bolus. Doctor B then prescribed 'Dilantin slow IV' on the resuscitation chart.
- After confirmation with Doctor B, Nurse E administered an undiluted dose of **280mg phenytoin via IV bolus in about 3 minutes**.
- Patient immediately developed bradycardia, then cardiac arrest. Upon resuscitation, patient regained circulation 16 minutes later and was transferred to the Paediatric Intensive Care Unit.

For safe administration of phenytoin

Undiluted phenytoin should be given as "slow IV infusion"

1. Administration rate

Adult: do not exceed 50mg/minute

Paediatrics: do not exceed 1-3mg/kg/minute (maximum 50mg/minute)

2. Drug concentration

Each 5ml ampoule contains 250mg phenytoin sodium

Dilution of phenytoin into intravenous infusion is not recommended due to lack of solubility and resultant precipitation.

3. Other tips

Do's

- Use large vein and large gauge intravenous catheter for administration
- **Use syringe pump for administration** and cardiac monitor to detect cardiac arrhythmia
- Flush with 0.9% NaCl through the same catheter before and after to avoid local venous irritation due to alkalinity of phenytoin sodium solution

Don'ts

- No intramuscular injection, as risk of slow and erratic absorption and risk of tissue necrosis
- No mixing in other IV solutions (e.g. dextrose solution) or with other drugs as pH alteration can cause drug precipitation

High alert medication infusion

- A newborn baby was on ECMO and continuous renal replacement therapy. She was found to have hypokalaemia despite two rounds of potassium chloride infusion. Doctor hence prescribed a third dose of IV potassium chloride infusion.
 - Two nurses independently checked the order, prepared and administered the dose.
 - During the infusion, patient developed bradycardia, followed by asystole.
 - The infusion was stopped immediately. Patient's serum potassium level was found higher than normal.
 - With active medical treatment and renal replacement therapy, patient's sinus rhythm returned within 5 minutes and serum potassium level decreased subsequently.
- A patient was initially on subcutaneous morphine infusion at 2 mg over 24 hours at 1ml/hr.
 - After the shift handover, Nurse A checked the syringe pump settings but misinterpreted the prescription order as 2ml/hr.
 - Nurse A asked Nurse B about the infusion rate but Nurse B was managing a deteriorating patient. Nurse B checked the prescription and agreed with Nurse A. Nurse A hence changed the infusion rate to 2ml/hr.
 - The infusion rate was later found to be incorrect when the patient was transferred to a palliative ward around 4 hours later.
- A patient on mechanical ventilation, was prescribed with 1mg/ml midazolam infusion at 8 ml/hr.
 - Nurse A and Nurse B prepared a new set of midazolam infusion for maintenance together.
 - As Nurse B was engaged in doctors' round, Nurse A performed the syringe pump setting alone.
 - 19 minutes later, the infusion rate was found to be running at 42ml/hr instead.
- Morphine sedation was given to a paediatric patient on mechanical ventilation.
 - In view of hypotension, the concentration of IV morphine was reduced by half. Nurse A administered the new morphine infusion and set up the drug delivery programme by manually entering the morphine concentration, while Nurse B was reading out the doctor's prescription in Clinical Information System at a distance.
 - Nurse A did not perform a reciprocal cross-check with Nurse B.
 - The morphine infusion was later found to be running at an incorrect rate, due to the incorrect morphine concentration entered into the smart infusion pump.

Infusion tips

- Drug concentration and infusion rate are 2 common areas of errors.
- Perform independent double check on the 5 Rights (right patient, right time, right drug, right dose and right route) against the prescription and pump settings before commencing the infusion and leaving the patient. Be cautious of decimal points.
- Make reference to standardised dosing/infusion tables to minimise calculation error
- Use commercially pre-mixed IV/epidural solutions if available
- Display drug information charts for easy reference to medical, nursing and pharmacy staff, e.g. compatibility, maximum dose and equianalgesic doses for opioids in all patient care units
- Keep only one strength of parenteral narcotic/opioids in the ward (if applicable)

Reference: [Safety Solutions on High Alert Medications](#)

EDITORIAL BOARD

Editor-in-Chief: Dr Sara HO, CM(PS&RM), HAHO

Board Members: Dr Ian CHAN, Dep SD(Q&S), KEC; Dr W M CHEUNG, SD(Q&S), KWC; Mr Brian CHING, P(CPO), HAHO; Dr Jackie CHEUNG, SM(PS&RM), HAHO; Ms Katherine PANG, M(PS&RM), HAHO; Mr M N CHAN, M(PS&RM), HAHO; Mr Charles CHEUNG, M(PS&RM), HAHO.

Suggestion or feedback is most welcome. Please email us through HA intranet address: [HO Patient Safety & Risk Management](#)